

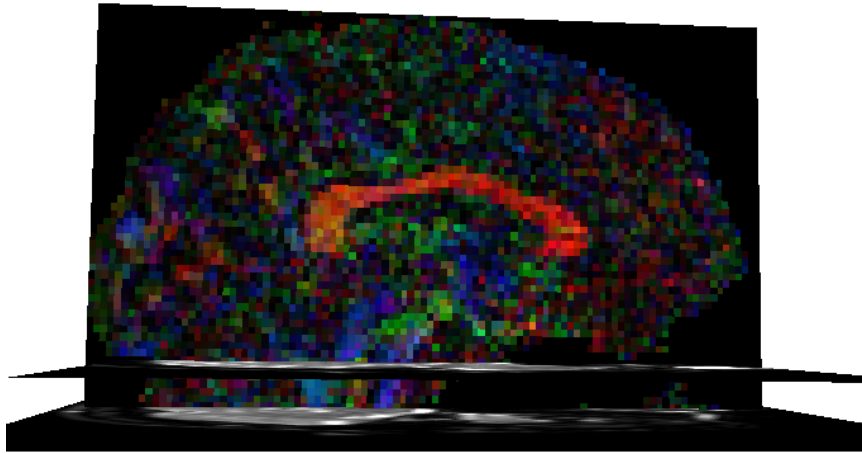
# Supplementary Material

---

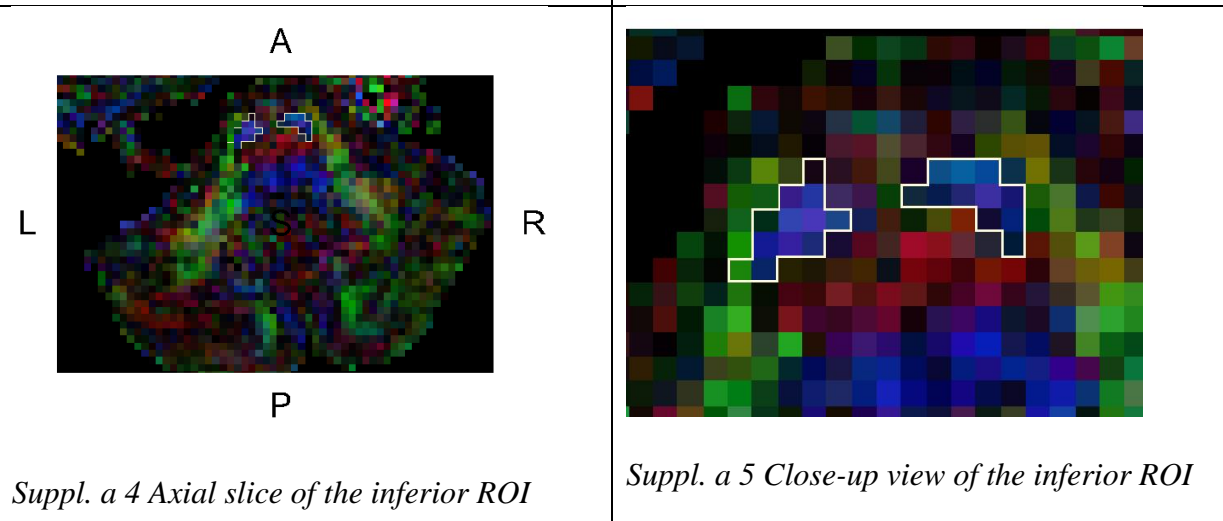

## **Regions of interest (ROIs) of the cortico-spinal tract (CST) and the superior cerebellar peduncle (SCP)**

Localization of ROIs used to reconstruct the left and the right CST and the left and the right SCP.

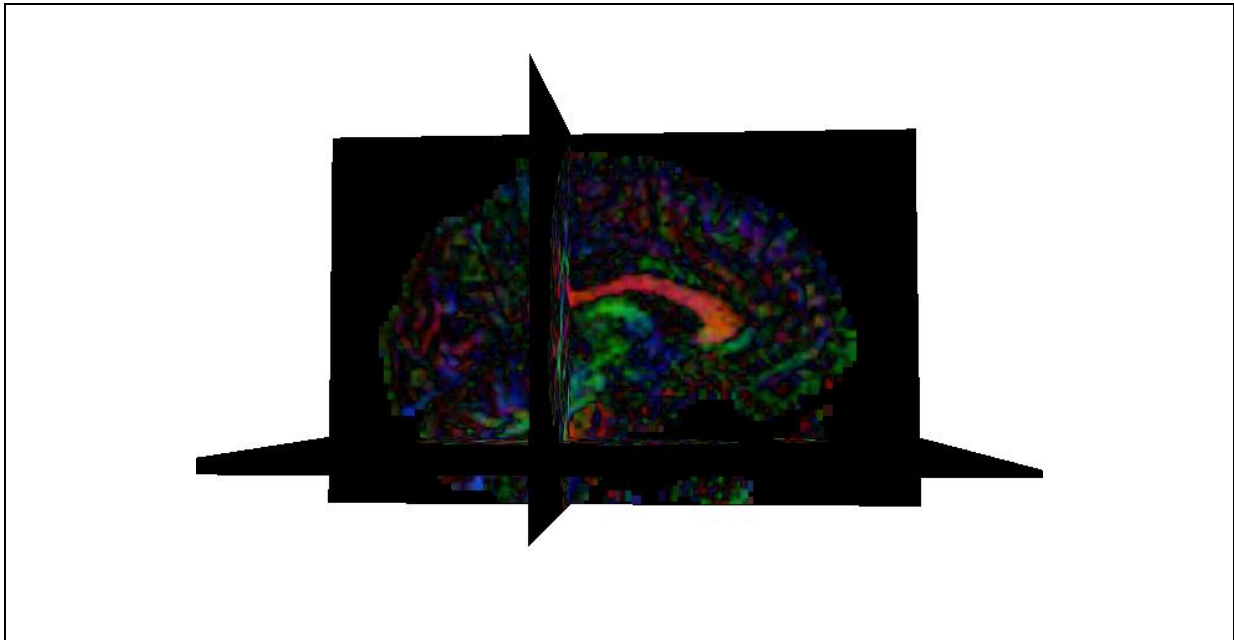
a: CST.



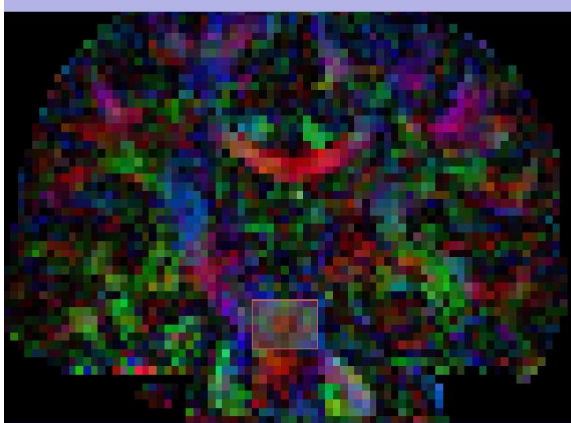
Suppl. a 1 Position of the axial slices where ROIs were drawn, in 3D view




**b: SCP.**



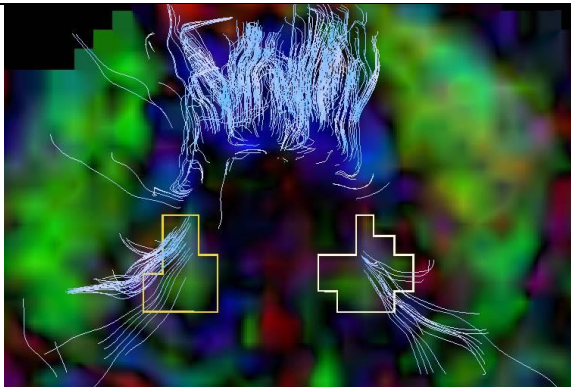
*Suppl. b 1 Position of slices where ROIs were drawn, in 3D view*



*Suppl. b 2 First inclusion ROI, coronal slice*



*Suppl. b 3 Close-up view of the first inclusion ROI*



*Suppl. b 4 Second inclusion ROI, axial slice*

A: anterior, P: posterior, R: right, L: left